



Single-Stage Reconstruction

A Guide to Collaboration with General Surgical Colleagues – Planning Ahead



Not for distribution in USA

By Loren Eskenazi, MD
F.A.C.S.

Introduction

The advent of stereotactic guided needle biopsy and the wide acceptance of skin-sparing mastectomy techniques have opened the door to achieving excellent results with immediate implant reconstruction in a single stage. Therefore, when an excisional biopsy is necessary, it is important to keep in mind the possibility of future reconstruction when planning the incision. The orientation and location of the surgical biopsy incision affects the final aesthetic outcome and long-term results. Traditionally, most surgeons have been instructed to make incisions radially along Langer's lines because these are more cosmetic and heal with superior scars. In actuality, the breast is one of the areas where this is not always the case.

incisions to avoid

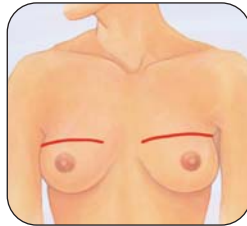


Figure A
violation of bra line

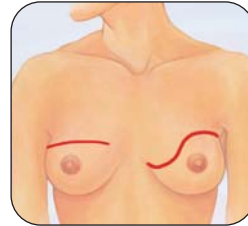


Figure B
unmatched scars

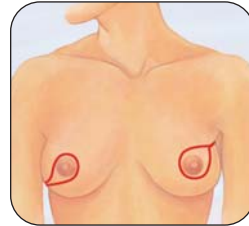


Figure C
unmatched scars

ideal incisions

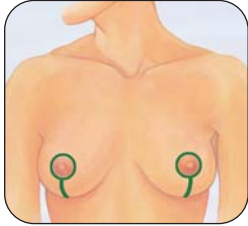


Figure D

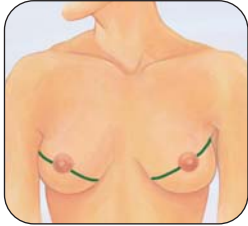


Figure E

Like the face, the breast has aesthetic units that may be used to guide incision placement in an aesthetically pleasing pattern. It is better, whenever possible, to use symmetrical mirror image incisions. Aesthetic incisions are placed within the bra line or nipple areola complex or are hidden from view when a patient looks down at herself or is seen by others wearing a bra. *(See cases #1 and 2 on pg. 9)*

Specific Incisions:

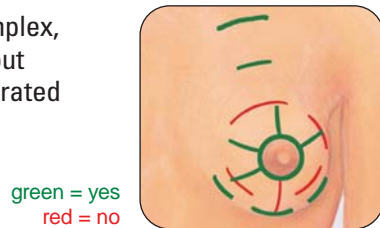
It is always prudent to perform a biopsy as if a woman may have a mastectomy and reconstruction in the future, since the biopsy results can be a surprise to the patient and the physician alike.

Small-breasted women: It is better whenever possible in a small-breasted woman to locate the incision within or close to the aesthetic unit of the nipple/areola complex or below the bra line. In a small-breasted woman, the skin in the inferior lateral quadrant is the most important to preserve when trying to achieve an excellent result in one stage. Thus, the incision should be oriented to maximize the available skin in this area. Adding an axillary counter-incision for lymph node dissection is often preferable to extending the skin-sparing mastectomy incision in small-breasted women.

In a case where the tumor is located significantly above the nipple areola complex, an incision perpendicular to Langer's lines allows you to excise the scar without compromising your result. In a larger-breasted woman, this incision is incorporated into the WISE-pattern mastectomy. (See Fig. 1 on pg. 6)

NOTE: When the incision is visible in a scooped-neck shirt (as in port placement for chemotherapy) Langer's lines can serve as a guide since the nipple areola complex is far away and a significant skin bridge exists for the superior flap.

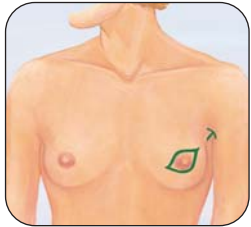
Figure F



Ideal biopsy incisions and incisions to avoid

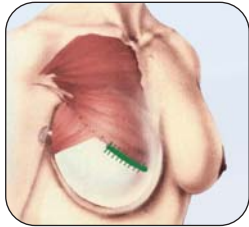
When performing a biopsy on a mass in the outer quadrant, it is preferable to orient the incision perpendicular to Langer's lines. The most challenging situation in small-breasted women is when the tumor is located beneath the nipple/areola complex (NAC) in the 6 o'clock position, close to the infra-mammary fold (IMF). When it is not possible to reach the tumor through a peri-areolar type incision, a small incision in the IMF can be used, providing there is an adequate skin bridge between the IMF and the NAC. In rare cases with small-breasted women, when the skin of the lower pole is significantly violated, it may be necessary to place the implant entirely submuscularly or to perform an autogenous tissue procedure.

Figure G



Ideal mastectomy incisions

Figure H



Ideal mastectomy incisions

NOTE: The author does not prefer purse-string closures directly over an implant, but it is an option if the technique has been perfected and is preferred by the plastic surgeon.

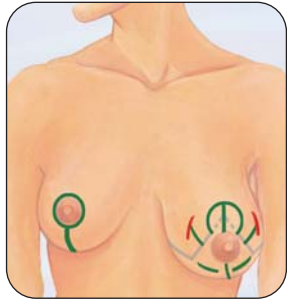
Specific Incisions:

Large-breasted women: In a large-breasted woman who desires symmetry in the nude, the contralateral breast will require a lift and/or reduction. A WISE-pattern incision or a variation thereof is usually the best choice. For a minimally or moderately ptotic breast (Grades 1 or 2 ptosis) a Bennelli circumareolar or Renault-type lateral mastopexy may be used. *(Fig. J on pg. 6)*

For significant ptosis (Grade 3 or 4 ptosis) the WISE-Pattern mastectomy incision is preferable with a traditional anchor or lollipop incision on the opposite side. *(Fig. K on pg. 6)* This is a particularly well-suited incision when biopsy falls within the skin area to be removed. *(Fig. I on pg. 6)* In order to achieve the most ptosis possible, the skin flaps are marked generously (T limb \geq 7cm) and the lower pole skin is depithelialized and sutured to the inferior edge of the pectoralis major once it is released. This provides two layers of coverage in case there is marginal skin necrosis of the mastectomy flaps at the "T" junction.

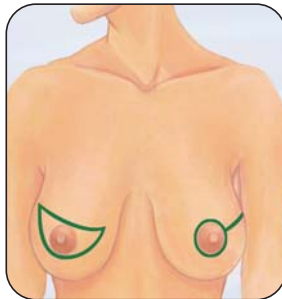NOTE: *It is always preferable for the general surgeon to preserve the intercostal perforators medially to provide adequate circulation to the distal tip of the medial flap. Be cautious when using this type of incision in a smoker. For a patient with a history of smoking, use the incision illustrated in Figure J.*

Figure I



Ideal and erroneous incision types

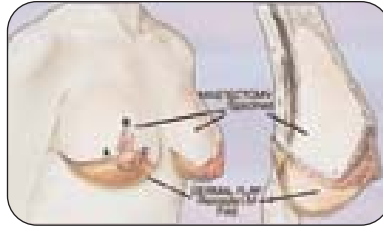
Figure J



Mastectomy incisions of large-breasted woman

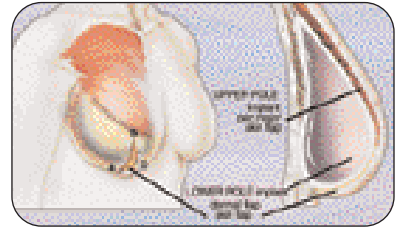
green = yes
red = no

Figure K



Ideal incisions: WISE-Pattern mastectomy with immediate reconstruction

Figure L



SSM and extensions in dotted lines (incisions and extensions)

Surgical Timing

It is better for the patient to have a shorter amount of time under general anesthesia. Thus, it is highly recommended that the general and plastic surgeons work at the same time whenever possible. Two sets of instruments and two surgical fields are maintained so that the general surgeon can proceed with mastectomy while the plastic surgeon raises a flap for an autologous tissue case, or adjusts the contralateral breast in an implant reconstruction. In the case of a bilateral implant reconstruction, the plastic surgeon begins reconstruction on one side while the general surgeon completes the second mastectomy.

Contralateral Breast:

Symmetry is of paramount importance in breast surgery. It is better to use similar incisions on both breasts whenever possible. It is also possible, with experience, to learn how to anticipate the final result over time, thus making a single-stage procedure possible. The 'normal' breast will descend over time and the implant reconstruction will rise slightly as a capsule is formed (this occurs minimally even in the softest breasts). Breast augmentation is often required in small-breasted women to achieve superior pole fullness or symmetry in the nude. *(See case #9 on pg. 11)* An augmentation/mastopexy is sometimes the best solution for the ptotic breast. *(See case #11 on pg. 12)*

If a mastopexy or breast reduction is needed on the contralateral side, a WISE-Pattern mastectomy is usually the best choice. *(See case #10 and 11 on pp. 11 - 12)*

Post-reconstruction radiation with implants:

There are several important considerations to obtaining soft long-term implant reconstruction results after radiation therapy:

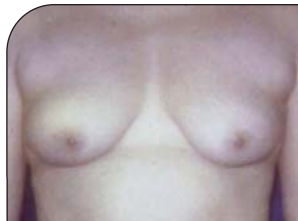- 1) The implant should be placed prior to radiation.
- 2) Those patients with more skin and larger implant pockets can, with an aggressive massage regime, keep their implants soft during and after radiation.
- 3) Some physicians also feel that over-expanding the implant during radiation and subsequent removal of saline after radiation is completed may be helpful.
- 4) The author also makes use of a surgical bandeau to hold the implant in position at the earliest signs of elevation.
- 5) In the author's experience, pharmacological agents such as Oral Papavarine can be useful.

At right is an example of a patient who has had a bilateral mastectomy, who has had the left breast radiated after reconstruction in a single-stage with a Spectrum® implant.



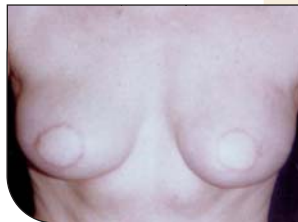Single-Stage Reconstructions

Case 1



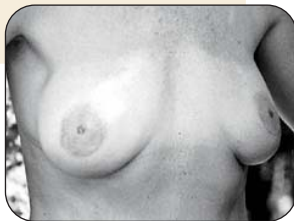Case #1 & 2

Pre and post immediate
bilateral TRAM flap procedure
with circumareolar incisions



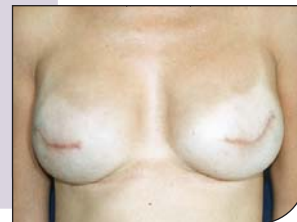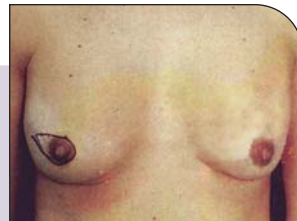3 weeks post-op

Case 2

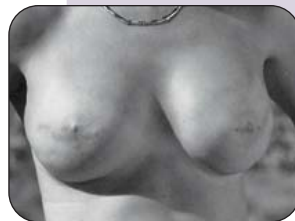

Case #3

Pre and post immediate
bilateral implants

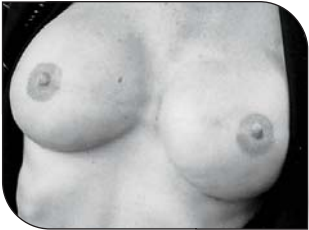

3 weeks post-op

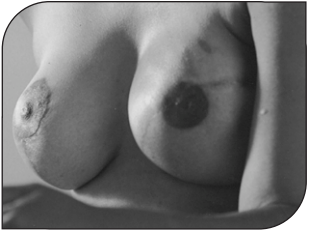
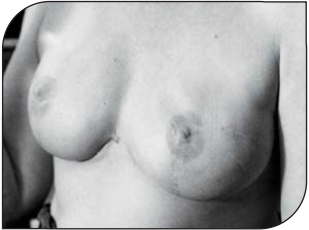
1 year post-op

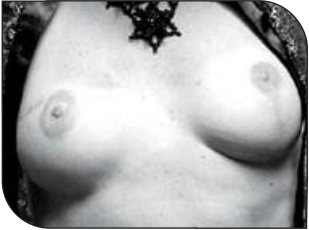Single-Stage Reconstructions



Case #4 & 5
Pre and post immediate
bilateral implant reconstruction



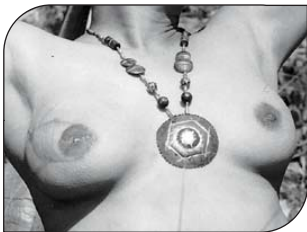Case #6 & 7
Unmatched scars with
implant reconstruction and
contralateral mastopexy



Single-Stage Reconstructions

Case #8

Unmatched scars with TRAM reconstruction of right breast



Case #9

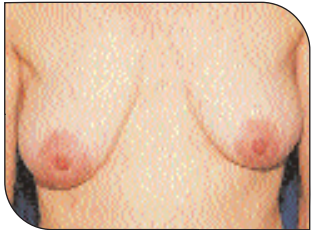
Implant reconstruction on left breast with augmentation of the right breast



Case #10

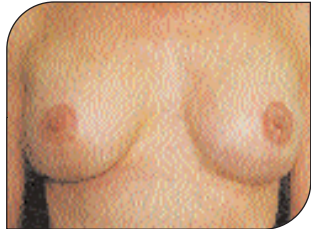WISE-Pattern mastectomy: Right breast mastectomy and left breast augmentation/mastopexy

Single-Stage Reconstructions



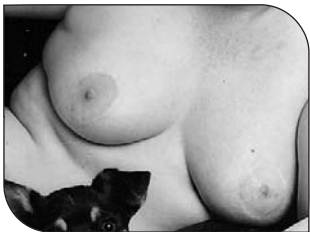Case #11

WISE-Pattern mastectomy
left breast mastopexy with
augmentation of the right breast



Case #12

TRAM Flap reconstruction on
right breast with circumareolar
mastopexy of left breast





Corporate Headquarters:
Santa Barbara, CA, 93111 USA
www.mentorcorp.com

Customer Service:
+1 805 879 6000

*Manufacturer
Gels & Beckers:*

Mentor Medical Systems B.V.
Zernikedreef 2
2333 CL Leiden
The Netherlands

*Manufacturer
Salines & Spectrums:*

Mentor
3041 Skyway Circle North
Irving, TX 75038 USA

International Operations

Mentor Medical Systems Australia, Pty. Ltd. • Tel: +61 3 9890 9444 Toll Free: +1 800 338 160 Fax: +61 3 9890 9777

Mentor Medical Systems Canada, Inc. • Tel: +1 905 725 7763 Toll Free: +1 800 668 6069 Fax: +1 905 725 7340

Mentor Benelux B.V. • Tel: +32 15 459156 Fax: +32 15 459157

Mentor Deutschland GmbH • Tel: +49 8116 00500 Fax: +49 8116 005011

Mentor Medical Systems France, S.A. • Tel: +33 1 46 01 30 54 Fax: +33 1 46 01 30 55

Mentor Medical Systems Iberica, S.L. • Tel: +34 91 562 2700 Fax: +34 91 563 3951

Mentor Medical Italia, S.r.l. • Tel: +39 0 2 880 7761 Fax: +39 0 2 7209 3710

Mentor Medical Systems Ltd., U.K. • Tel: +44 1235 768758 Fax: +44 1235 768780